


Thoracic Spinal Anesthesia in a Patient with Peritoneal Tuberculosis with Massive Ascites and Bilateral Pleural Effusion for Laparotomy

Dwi Lunarta Docterina Sutanti Siahaan ^{1*}, Jadeny Sinatra ¹, Ronald T.H. Tambunan ¹, Agus Prima ²

¹ Faculty of Medicine, Universitas Methodist Indonesia, Medan, Indonesia

² Division of Anesthesiology and Intensive Care, National Center of Research and Education Institute (NCREI), Medan, Indonesia

*Corresponding Author: Dwi Lunarta Docterina Sutanti Siahaan, E-mail: rinasiahaan72@gmail.com 

ARTICLE INFO

Article history:

Received

17 March 2026

Revised

7 May 2026

Accepted

30 June 2026

Manuscript ID:

JSOCMED 17032026-56-4

Checked for Plagiarism: Yes

Language Editor: Rebecca

Editor-Chief: Prof. Aznan Lelo, PhD

Keywords

ABSTRACT

Peritoneal tuberculosis is an extrapulmonary form of tuberculosis with nonspecific clinical manifestations, such as ascites and abdominal pain, often leading to delayed diagnosis. In advanced conditions, massive ascites combined with bilateral pleural effusion may significantly impair respiratory function and increase perioperative risk. General anesthesia, commonly used for laparotomy, may further worsen pulmonary complications in such high-risk patients. We report a case of a 23-years-old female with peritoneal tuberculosis complicated by massive ascites and bilateral pleural effusion who underwent laparotomy under thoracic spinal anesthesia. The patient presented with abdominal distension, dyspnea, anemia, and hypoalbuminemia, indicating a compromised physiological status. Considering the risks associated with general anesthesia, thoracic spinal anesthesia was selected. The procedure was successfully performed with stable intraoperative hemodynamics and no significant respiratory complications. Thoracic spinal anesthesia is a feasible regional technique for abdominal surgery, offering better respiratory outcomes and recovery compared to general anesthesia. This case demonstrates its potential as a safe alternative in high-risk patients undergoing laparotomy.

Thoracic Spinal Anesthesia, Peritoneal Tuberculosis, Massive Ascites, Bilateral Pleural Effusion, Laparotomy

How to cite: Siahaan DLDS, Sinatra J, Tambunan RTH, Prima A. Thoracic Spinal Anesthesia in a Patient with Peritoneal Tuberculosis with Massive Ascites and Bilateral Pleural Effusion for Laparotomy. *Journal of Society Medicine*. 2026; 5 (6): 226-233. DOI: <https://doi.org/10.71197/jsocmed.v5i6.286>

INTRODUCTION

Tuberculosis remains a major global health problem and continues to contribute significantly to morbidity and mortality, particularly in developing countries. Although pulmonary tuberculosis is the most common presentation, extrapulmonary involvement accounts for a substantial proportion of cases, including infection of the peritoneum [1,2]. Peritoneal tuberculosis is a relatively uncommon manifestation, often characterized by nonspecific clinical features such as abdominal pain, weight loss, fever, and ascites, which frequently lead to delayed diagnosis and misinterpretation as other intra-abdominal conditions[2,3].

The clinical complexity increases when peritoneal tuberculosis is accompanied by massive ascites or pleural effusion. Fluid accumulation in the abdominal and pleural cavities can significantly impair respiratory mechanics by elevating the diaphragm and reducing lung expansion, thereby predisposing patients to hypoxemia and perioperative respiratory complications [4]. In addition, patients with advanced tuberculosis often present with anemia, hypoalbuminemia, and systemic inflammation, which further compromise their physiological reserve and increase their surgical risk [5]. In such high-risk patients, the choice of anesthetic

technique is a critical component of perioperative management. General anesthesia is commonly used for laparotomy; however, it is associated with several disadvantages, including respiratory depression, hemodynamic instability, and an increased incidence of postoperative pulmonary complications, particularly in patients with pre-existing pulmonary impairment [6]. These risks are particularly relevant in patients with pleural effusions and compromised respiratory function.

Regional anesthesia techniques have emerged as valuable alternatives for selected high-risk patients [1]. Thoracic epidural anesthesia has been shown to provide effective analgesia and reduce pulmonary complications in upper abdominal surgery, highlighting the potential benefits of avoiding general anesthesia in patients with a limited respiratory reserve [6]. Furthermore, advances in spinal anesthesia techniques have demonstrated that thoracic spinal anesthesia can be safely performed and tailored to provide a segmental blockade suitable for abdominal procedures [7]. Recent evidence suggests that thoracic spinal anesthesia is a feasible and effective technique for abdominal surgery, offering improved postoperative outcomes and reduced pulmonary complications compared with general anesthesia [8]. However, its application in patients with complex conditions, such as peritoneal tuberculosis with massive ascites and bilateral pleural effusion, remains limited and requires further clinical consideration. Therefore, this case report aims to describe the use of thoracic spinal anesthesia in a patient with peritoneal tuberculosis, massive ascites, and bilateral pleural effusion undergoing laparotomy and to highlight its potential role as a safe and rational anesthetic alternative in such challenging clinical scenarios [9,10].

METHOD

This study was conducted as a descriptive observational case report involving a single patient diagnosed with peritoneal tuberculosis complicated by massive ascites and bilateral pleural effusion who underwent laparotomy under thoracic spinal anesthesia. A case report is a descriptive study that provides detailed information on the clinical presentation, diagnostic evaluation, management, and outcomes of individual patients, particularly in rare or complex clinical scenarios [11]. The methodology of this report was structured according to standard scientific writing principles, which include study design, subject description, data collection, data analysis, and ethical considerations [12]. The subject of this study was a 23-year-old female patient treated in a hospital setting, and all relevant clinical data were systematically documented.

Data were collected retrospectively from the patient's medical records, including demographic information, clinical history, physical examination findings, laboratory investigations, imaging results, anesthetic management, intraoperative monitoring, and postoperative outcomes. The case is presented in a chronological and structured manner to ensure clarity and reproducibility of clinical decision-making [11]. Data analysis in this study was performed using a descriptive approach without statistical testing, as case reports are not intended to establish statistical associations but to provide clinical insights and highlight unique or complex medical conditions [11]. Therefore, no inferential statistical methods or power analysis was applied. Ethical considerations were maintained by ensuring patient confidentiality and anonymization of all identifying information. Written informed consent was obtained from the patient prior to publication, in accordance with recommended standards for case report reporting [12].

RESULT

Patient Characteristics and Clinical Presentation

A 23-year-old female patient was admitted with progressive abdominal distension and shortness of breath. The patient had a prior history of intestinal tuberculosis and reported worsening symptoms over the past month, including inability to pass stool and flatus, decreased appetite, and significant weight loss, indicating a chronic and progressive disease course. On admission, the patient appeared clinically ill with signs of respiratory discomfort. Vital signs showed a respiratory rate of 22 breaths per minute, oxygen saturation of 99% with nasal oxygen supplementation at 2 liters per minute, blood pressure of 111/82 mmHg, and heart rate of 95 beats per minute. These findings indicated relatively stable hemodynamics with underlying respiratory compromise.

Abdominal examination revealed marked distension with positive shifting dullness, which was consistent with massive ascites. Bowel sounds were decreased, suggesting impaired gastrointestinal motility without signs of acute peritonitis.

Table 1. Patient Characteristics and Clinical Presentation

Parameter	Findings
Age	23 years
Sex	Female
Chief Complaint	Abdominal Distension, Dyspnea
Additional Symptoms	Constipation, Inability To Pass Flatus, Weight Loss
Past Medical History	Intestinal Tuberculosis (1 Year Prior)
Treatment History	Anti-Tuberculosis Therapy For 9 Months
Admission Condition	Progressive Abdominal Distension With Respiratory Discomfort

Physical Examination Findings

Further systemic examination demonstrated decreased breath sounds in both lung fields, consistent with bilateral pleural effusion, contributing to reduced lung expansion and increased work of breathing. Cardiovascular examination revealed normal heart sounds without murmurs, while neurological examination was within normal limits. Peripheral perfusion was adequate, and peripheral edema was not observed.

Table 2. Physical Examination Findings

System	Findings
Vital signs	Blood Pressure 111/82 MmHg, Heart Rate 95 Beats/Min, Respiratory Rate 22/Min, SpO ₂ 99% (O ₂ 2 L/Min), Temperature 36.9°C
Respiratory	Symmetrical Chest Movement, Vesicular Breath Sounds, No Wheezing Or Rhonchi
Cardiovascular	Normal Heart Sounds, No Murmurs
Abdomen	Distension, Positive Shifting Dullness, Decreased Bowel Sounds
Neurological	Compos Mentis
Peripheral	Warm Extremities, No Edema

Laboratory and Imaging Findings

Laboratory investigations revealed several abnormalities indicating systemic involvement and poor nutritional status. Hematological examination revealed anemia with a hemoglobin level of 9.8 g/dL, while leukocyte and platelet counts remained within normal limits. Coagulation parameters were within normal ranges. Electrolyte analysis demonstrated mild hyponatremia and hypochloremia, while potassium levels remained within normal limits. Liver function testing revealed significant hypoalbuminemia with a serum albumin level of 2.04 g/dL, suggesting chronic disease and malnutrition.

Table 3. Laboratory Findings

Parameter	Result	Normal Range
Hemoglobin	9.8 g/dL	12.5–14.5
Leukocytes	10.7 ×10 ³ /μL	5–11
Platelets	325 ×10 ³ /μL	150–450
Bleeding time	3 minutes	1–5
Clotting time	7 minutes	5–15
Sodium	135.9 mEq/L	136–145
Potassium	3.39 mEq/L	3.2–5.5
Chloride	95.2 mEq/L	97–110
Albumin	2.04 g/dL	3.0–5.0
CA-125	410 U/mL	≤35
CEA	0.9 ng/mL	≤5
Random blood glucose	89 mg/dL	<200
IGRA	Negative	Negative

Tumor marker evaluation showed markedly elevated CA-125 levels of 410 U/mL, which may mimic intra-abdominal malignancy. However, interferon-gamma release assay testing for tuberculosis was negative. Random blood glucose levels were within normal limits.

Imaging and Supporting Diagnostic Findings

Chest radiography demonstrated bilateral pleural effusion, indicated by blunting of the costophrenic angles and the presence of a meniscus sign on both sides (Appendix Figure 1).

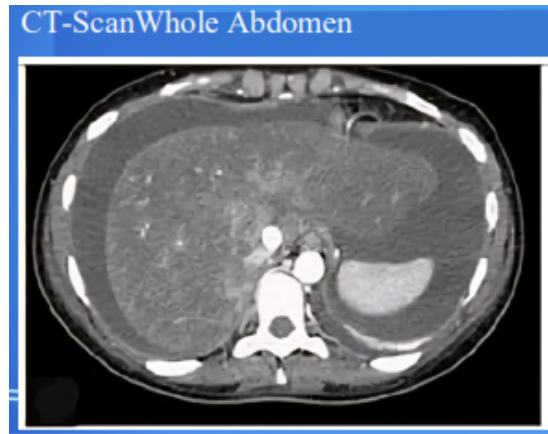


Figure 1. Chest X-ray Showing Bilateral Pleural Effusion with Meniscus Sign

Abdominal ultrasonography revealed massive ascites with internal debris, supporting the diagnosis of peritoneal inflammation. Computed tomography of the abdomen further confirmed massive ascites with features suggestive of peritonitis, accompanied by bilateral pleural effusion and findings consistent with pulmonary tuberculosis (Appendix Figure 2).

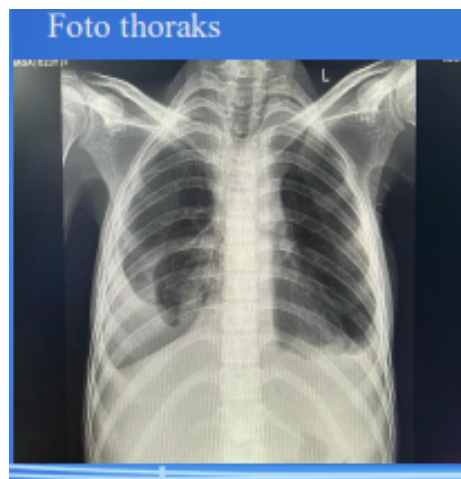


Figure 2. Abdominal Ultrasound Demonstrating Massive Ascites with Internal Debris

Cytological examination of the pleural fluid revealed predominantly mature lymphocytes, macrophages with foamy cytoplasm, and mesothelial cells, without evidence of malignant cells. These findings support a non-malignant inflammatory process.

Perioperative Risk Assessment, Anesthetic Management, and Outcome

The patient was categorized as a high-risk surgical candidate because of multiple physiological impairments. Massive ascites increases intra-abdominal pressure, leading to diaphragmatic elevation and reduced lung expansion, thereby predisposing the patient to perioperative hypoxemia. In addition, bilateral pleural effusion

further compromised respiratory function, increasing the risk of respiratory failure, particularly in the setting of general anesthesia and mechanical ventilation.

From a hemodynamic perspective, the presence of massive ascites suggested relative hypovolemia due to third spacing of fluids. This condition increased the likelihood of significant hypotension during the induction of general anesthesia. Furthermore, conventional lumbar spinal anesthesia was considered suboptimal due to the risk of extensive sympathetic blockade, which could result in profound hemodynamic instability. Additional perioperative concerns included an increased risk of aspiration due to elevated intra-abdominal pressure, as well as altered pharmacokinetics of anesthetic agents secondary to hypoalbuminemia, which may affect drug distribution and protein binding. Considering these factors, thoracic spinal anesthesia was selected as the anesthetic technique for laparotomy. A thoracic spinal approach was performed under strict aseptic conditions to achieve segmental sensory blockade appropriate for upper abdominal surgery. Following confirmation of cerebrospinal fluid flow, an intrathecal local anesthetic was administered to produce adequate anesthesia while limiting the extent of sympathetic blockade. This approach was intended to maintain hemodynamic stability and minimize the risk of hypotension. The use of thoracic spinal anesthesia also allowed avoidance of airway manipulation and mechanical ventilation, thereby reducing the risk of respiratory deterioration in the presence of massive ascites and bilateral pleural effusion [13]. In addition, the segmental nature of the block provided more controlled anesthetic spread compared to conventional lumbar spinal anesthesia.

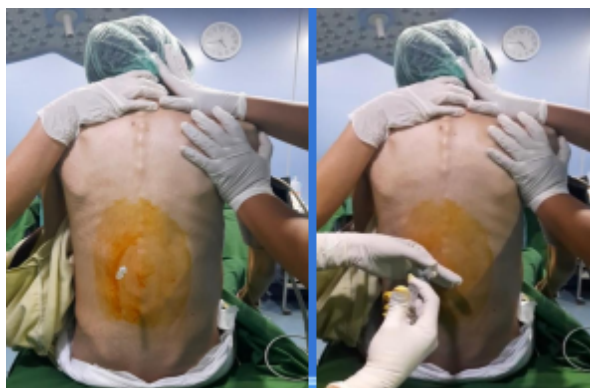

Figure 3. Administration Of Thoracic Spinal Anesthesia in the Sitting Position Under Aseptic Conditions

The anesthetic procedure and intraoperative conditions are illustrated in Appendix Figures 3 and 4. Appendix Figure 3 shows the administration of thoracic spinal anesthesia in the sitting position under aseptic conditions, while Appendix Figure 4 shows the intraoperative condition of the patient, including monitoring and surgical positioning during laparotomy (see Appendix Figures 3 and 4).

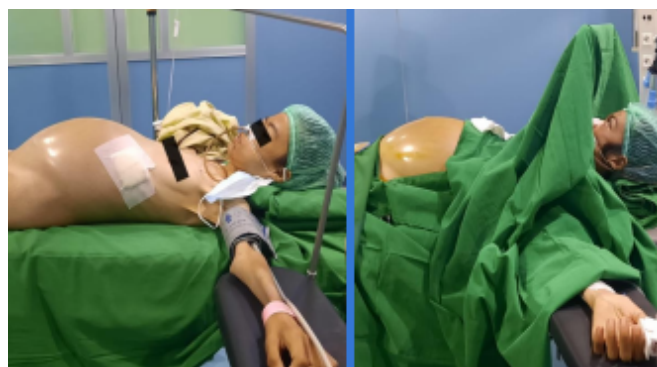

Figure 4. Intraoperative Condition During Laparotomy Showing Patient Positioning and Monitoring Under Aseptic Conditions

During the intraoperative period, the patient remained hemodynamically stable, without significant fluctuations in blood pressure or heart rate. Adequate anesthesia was achieved throughout the procedure, and

no intraoperative respiratory complications were noted. The surgical procedure was successfully completed without the need for general anesthesia. Postoperatively, the patient demonstrated stable recovery with no immediate complications related to the anesthesia. Respiratory function remained adequate, and no signs of hemodynamic instability were observed during the early postoperative period.

DISCUSSION

Peritoneal tuberculosis is a challenging clinical condition because of its nonspecific presentation and ability to mimic other intra-abdominal pathologies, including malignancies [14]. Patients commonly present with ascites, abdominal distension, weight loss, and systemic symptoms, which may delay diagnosis and appropriate management [2,3]. In this case, the presence of massive ascites and markedly elevated CA-125 levels further complicated the clinical picture, as these findings are often associated with intra-abdominal malignancies, potentially leading to misdiagnosis [15,16]. The coexistence of bilateral pleural effusion and massive ascites significantly contributed to respiratory compromise in this patient. Increased intra-abdominal pressure due to ascites can elevate the diaphragm and reduce lung volumes, while pleural effusion further impairs ventilation [17]. These conditions collectively increase the risk of perioperative hypoxemia and respiratory failure, particularly when general anesthesia with mechanical ventilation is employed [4].

From a perioperative perspective, patients with peritoneal tuberculosis often present with multiple physiological derangements, including anemia, hypoalbuminemia, and chronic inflammation [18,19]. Hypoalbuminemia, in particular, reflects poor nutritional status and systemic inflammatory response, which can alter drug distribution and increase perioperative risk [5,24]. Additionally, massive ascites contributes to relative hypovolemia due to third-spacing, predisposing the patient to significant hypotension during anesthetic induction [2]. General anesthesia is the conventional technique for laparotomy; however, in high-risk patients, such as this, it may exacerbate respiratory compromise and increase the likelihood of postoperative pulmonary complications. Mechanical ventilation in the presence of pleural effusion may worsen ventilation-perfusion mismatch and increase the risk of respiratory failure [2]. Furthermore, the risk of aspiration is elevated due to increased intra-abdominal pressure, making airway management more challenging. Regional anesthesia techniques provide an alternative approach for selected patients. Thoracic epidural anesthesia has been shown to improve postoperative respiratory outcomes and reduce pulmonary complications in upper abdominal surgery, supporting the avoidance of general anesthesia in patients with compromised respiratory function [6]. Building on this concept, thoracic spinal anesthesia offers additional advantages, including rapid onset, dense sensory blockade, and better hemodynamic control through a more segmental block [7].

In this case, thoracic spinal anesthesia was selected to minimize both respiratory and hemodynamic risks. Compared to general anesthesia, this technique avoids airway manipulation and mechanical ventilation, thereby reducing the risk of respiratory deterioration [20]. Compared to conventional lumbar spinal anesthesia, thoracic spinal anesthesia provides a more controlled and segmental sympathetic blockade, thereby reducing the likelihood of profound hypotension [8]. Previous studies have demonstrated that thoracic spinal anesthesia is a feasible and effective technique for abdominal surgery, with benefits including reduced postoperative pain, faster recovery, and improved patient satisfaction [8,23]. The successful intraoperative and postoperative outcomes observed in this patient further support the role of thoracic spinal anesthesia as a safe and rational alternative in high-risk abdominal surgery [21,22].

CONCLUSION

Thoracic spinal anesthesia can be a safe and effective technique in patients with peritoneal tuberculosis complicated by massive ascites and bilateral pleural effusion undergoing laparotomy. In a high-risk case, significant respiratory compromise and hemodynamic vulnerability made general anesthesia hazardous, whereas thoracic spinal anesthesia provided reliable surgical conditions, stable intraoperative hemodynamics, and no respiratory complications. By avoiding airway instrumentation and mechanical ventilation, it minimizes pulmonary complications. These findings suggest that it may be an alternative to general anesthesia in selected patients with severe cardiorespiratory compromise; however, further studies are needed.

DECLARATIONS

None

CONSENT FOR PUBLICATION

The authors agree to the publication of this article in the Journal of Society Medicine.

FUNDING

This research did not receive any specific grants from any funding agency in the public, commercial, or not-for-profit sectors.

COMPETING INTERESTS

All authors have reviewed and approved the final version of the manuscript and have agreed to its publication in the Journal of Society Medicine.

AUTHORS' CONTRIBUTIONS

All authors have reviewed and approved the final version of the manuscript, and they all agree to be accountable for all aspects of the work.

ACKNOWLEDGMENTS

The authors gratefully acknowledge the institutional support from the Faculty of Medicine, Universitas Methodist Indonesia, and the Division of Anesthesiology and Intensive Care, National Center of Research and Education Institute (NCREI), Medan, Indonesia. No external funding was received, and no other individuals contributed to this study.

REFERENCE

1. Jackson TA, Thomas JM. Tuberculosis: The implications for anesthesia. *South African Fam Pract.* 2014;56(6):28-31.
2. Wu DC, Averbukh LD, Wu GY. Diagnostic and therapeutic strategies for peritoneal tuberculosis: A review. *J Clin Transl Hepatol.* 2019;7(2):140-148.
3. Siagian N, Arfijanto MV. Diagnostic Challenge Of Peritoneal Tuberculosis In Woman With Ascites. *Biomol Heal Sci J.* 2020;3(1):49.
4. Minamikawa M, Okazaki A, Yoshida N. Tuberculous pleuroperitonitis. *Clin Case Reports.* 2022;10(3):1-3.
5. Soeters PB, Wolfe RR, Shenkin A. Hypoalbuminemia: Pathogenesis and Clinical Significance. *J Parenter Enter Nutr.* 2019;43(2):181-193.
6. Faisal Irwanda, Andre Azhar, Dino Irawan. Thoracic Epidural Anesthesia Facilitating Upper Abdominal Surgery in the Presence of Malignant Pleural Effusion and Hepatic Metastases: A Case Report. *Biosci Med J Biomed Transl Res.* 2025;9(7):8165-8176.
7. Luiz Eduardo I, Marildo A G, Nathália Maluf G, Sylvio Valença de Lemos N. Spinal Anesthesia: Much More Than Single Shot of Hyperbaric Bupivacaine. *Int J Anesth Anesthesiol.* 2021;8(2).
8. Ellakany M. Thoracic spinal anesthesia is safe for patients undergoing abdominal cancer surgery. *Anesth Essays Res.* 2014;8(2):223.
9. Alicja B, Pawel B, Baranowska J, Tadeusz P. Sternal Tuberculosis: A Case Report. *J Wound Manag Res.* 2019;15(1):31-34.
10. Hussain T. Tuberculous pleural effusion – relapse or re-infection? Follow up of a case report and review of the literature. *Egypt J Chest Dis Tuberc.* 2016;65(4):859-861.
11. Ganesan P. How to Write Case Reports and Case Series Prasanth. *Int J Adv Med Heal Res.* 2022;37(2):102-106.
12. Eldawlatly AA, Meo SA. Writing the Methods Section. *Saudi J Anesth.* 2019;39(1):67-68.

13. A.Wahyu IL, Y. Dwiputra P. A Case of Tuberculous Peritonitis Accompanied By Tuberculous Pleuritis. *J Indones Sos Teknol.* 2024;5(4):1400-1407.
14. Di Buono G, Romano G, Amato G, Barletta G, Romano G, Adelfio N, et al. Surgical Management of Complicated Abdominal Tuberculosis: The First Systematic Review—New Treatments for an Ancient Disease and the State of the Art. *J Clin Med.* 2024;13(16).
15. Ruiz J, Ganji M, Canha C, Isache C. A Challenging Diagnosis of Ascites: A Case Report of Peritoneal Tuberculosis. *Case Rep Infect Dis.* 2018;2018:1-3.
16. Bogoslovskaya G. Peritoneal Tuberculosis Presenting as Chronic Ascites with Scrofula: A Case Report. *Cardiol Res Reports.* 2024;6(4):1-5.
17. Chen IH, Torng PL, Lee CY, Lee KH, Hsu HC, Cheng WF. Diagnosis of peritoneal tuberculosis from primary peritoneal cancer. *Int J Environ Res Public Health.* 2021;18(19).
18. Parvaresh S, Nikpour H, Hosseinasab A, Sinaei R, Jafari M. A case report of tuberculosis with ascites. *J Kerman Univ Med Sci.* 2021;28(4):409-411.
19. Diasa IMS, Padang MS, Madjar WYB. Peritoneal tuberculosis in remote area: a case report. *Intisari Sains Medis.* 2024;15(3):1256-1259.
20. Zebarjadi Bagherpour J, Bagherian Lemraski S, Haghbin Toutouchi A, Khoshnoudi H, Aghaei M, Kouchak Hosseini SP. Peritoneal tuberculosis pretending an acute abdomen; a case report and literature review. *Int J Surg Case Rep.* 2023;109:108507.
21. Sengupta S. Post-operative pulmonary complications after thoracotomy. *Indian J Anaesth.* 2015;59(9):618-626.
22. Karkhanis VS, Joshi JM. Pleural effusion: Diagnosis, treatment, and management. *Open Access Emerg Med.* 2012;4:31-52.
23. Ghozali I, Hamdi T, Yusmaidi Y, Sitepu JF. Single-shot thoracic spinal anesthesia (TSA) in a pediatric patient undergoing laparoscopic cholecystectomy: A case report. *Journal of Society Medicine.* 2022;1(3):87-90.
24. Iqbal A, Wijaya DW, Lubis B. Perioperative nutritional status of patients undergoing digestive laparotomy surgery. *Journal of Society Medicine.* 2022;1(3):96-101.