

## EARLY CONTINUOUS RENAL REPLACEMENT THERAPY IN PATIENTS WITH ST-ELEVATION MYOCARDIAL INFARCTION AND COVID-19 AFTER PERCUTANEOUS CORONARY INTERVENTION: A CASE REPORT

**Bastian Lubis<sup>1</sup>, Putri Amelia<sup>2</sup>, Muhammad Akil<sup>1</sup>, Vincent Viandy<sup>1</sup>, Ade Winata<sup>3</sup>, Yohanes WH George<sup>4</sup>**

<sup>1</sup>Department of Anesthesiology, Faculty of Medicine, Universitas Sumatera Utara, Indonesia

<sup>2</sup>Department of Child Health, Faculty of Medicine, Universitas Sumatera Utara, Indonesia

<sup>3</sup>Departement of Anesthesiology Pringadi Hospital Medan.

<sup>4</sup>Departement of Emergency and Intensive Care Unit Pondok Indah Hospital

**Corresponding Author:** Bastian Lubis, E-mail: [bastian.lubis@usu.ac.id](mailto:bastian.lubis@usu.ac.id)



### ABSTRACT

#### ARTICLE INFO

*Article history:*

Received

1 Juni 2022

Accepted

4 October 2022

Manuscript ID:

JSOCMED-221006-10

Checked for Plagiarism:

Yes

Language Editor:

Hendi Ishadi

Editor-Chief:

Prof. dr. Aznan Lelo,

PhD, Sp.FK

**Background:** Currently, there is no standardized approach to managing critically ill COVID-19 patients with acute kidney injury and ST-elevation myocardial infarction. Continuous renal replacement therapy is a routinely used technique in managing critical patients in the intensive care unit. This procedure is applicable in patients with unstable hemodynamic, renal, or non-renal indications, such as removing the excess urea and creatinine from patients with acute kidney injury or clearing the tumor necrosis factor from patients with systemic inflammations.

**Method:** This was a retrospective case report, after analysis of patient clinical data. The patient provided written informed consent to publish their case details and any accompanying images. The study protocol complies with the requirements of the institute's committee of Haji Adam Malik Hospital, Medan, Indonesia.

**Results:** This report presents a case of ST-Elevation myocardial infarction with COVID-19 infection and acute kidney injury who successfully managed by percutaneous coronary intervention and continuous renal replacement therapy. This patient was prepared for percutaneous coronary intervention and intubated with consideration of strict infection control. To improve the outcomes, we performed continuous renal replacement therapy with continuous venovenous hemodiafiltration mode. The patient improved with a stable hemodynamic and better renal function after 24 hours of continuous renal replacement therapy.

**Conclusion:** Early continuous renal replacement therapy might be beneficial in treating COVID-19 patients with AKI, who previously underwent percutaneous coronary intervention for ST-elevation myocardial infarction.

#### Keywords

Early Continuous Renal Replacement Therapy, COVID-19, percutaneous coronary intervention, AKI

## INTRODUCTION

Up to December 2020, Covid-19 has infected almost 80 million people globally, with 1.75 million related death. This disease is often accompanied by comorbidities. (1) In China, a study analyzing 44,672 confirmed cases showed that 4.2% of them had cardiovascular diseases. (2) Meanwhile, a study from the USA indicated that coronary artery diseases were among the most common comorbidities in COVID-19 patients, accounting for 11.1% of cases. (3)

Recent studies suggested that acute kidney injury (AKI) might be associated with COVID-19 severity and outcomes. (4) From a meta-analysis, the prevalence of AKI in Covid-19 patients was 17%. 77% of patients with AKI had a severe infection, 52% died. (5)

ST-Elevation Myocardial infarction (STEMI) is an emergency condition with a high incidence of sudden death. Revascularization of the occluded artery is required in STEMI management to reduce morbidity and mortality rate successfully. Acute kidney injury (AKI) is a renal complication that is frequently found in STEMI patients. STEMI might cause hemodynamic changes and increase endogenous vasoconstrictors' release, resulting in renal arteriolar vasoconstriction and kidney under perfusion. (6) The development of AKI in STEMI patients is associated with poor prognosis and higher morbidity and mortality rate. The incidence of AKI in STEMI patients ranges from 5-30%. (7) A cohort study in 3,210 acute myocardial infarction patients reported that 13% developed AKI, and renal replacement therapy (RRT) was required in 20% of those AKI patients. (8) Continuous renal replacement therapy (CRRT) has been used widely to treat critically ill patients with AKI. To this date, there is no standardized management of STEMI patients with AKI and COVID-19 infection.

This article discusses the case of an elderly patient with STEMI and COVID-19 who developed AKI during hospitalization and successfully treated with PCI and CRRT.

## METHOD

This was a retrospective case report, after analysis of patient clinical data. The patient provided written informed consent to publish their case details and any accompanying images. The study protocol complies with the requirements of the institute's committee of Haji Adam Malik Hospital, Medan, Indonesia.

## CASE DESCRIPTION

A 58 years old male was referred to our center with shortness of breath and chest pain. The patient was diagnosed with COVID-19 and myocardial infarction in the previous hospital before referred to our center for percutaneous coronary intervention (PCI). He also had a history of hypertension, type 2 diabetes mellitus, and smoking for approximately ten years.

Based on initial examination, we found that the vital signs were blood pressure: 164/90 mmHg, heart rate: 90 beats per minute, respiratory rate: 36 breaths per minute, and oxygen saturation: 99% on 15 liters O<sub>2</sub> via a non-rebreathing mask. The patient's consciousness was assessed with the Glasgow Coma Scale (GCS), and we found that he was vigilant (GCS 15).

We then performed electrocardiography, and the record showed an inferolateral infarction. The chest x-ray indicated pneumonia and hypertrophy of the left ventricle. We suspected an acute kidney injury from the laboratory results as there was a significant elevation in blood ureum and creatinine levels. The baseline ureum level was 140 mg/dL, and the creatinine was 43 mg/dL. The arterial blood gas analysis suggested respiratory acidosis. We also found an elevated lactic acid concentration, with 1.8 mmol/L.

The patient was scheduled for PCI the following day. Before conducting the procedure, we performed intubation and inserted central vascular access to minimize the contamination. After the catheterization, we performed CRRT with continuous venovenous hemodiafiltration (CVVHDF) mode with dose setting shown in figure 1 to treat renal and non-renal indications in this patient.

Before the CRRT, the patient was initially put on a mechanical ventilator with a BiPAP setting, PEEP 5 cmH<sub>2</sub>O, FiO<sub>2</sub> 80%, and oxygen saturation was 99%. After 24 hours of receiving CRRT, we saw an improvement of the hemostasis function, oxygenation, and perfusion with inotropic and vasopressor. The patient showed stable hemodynamic, better renal function (improvement in serum creatinine and ureum level), and lower lactic acid level, as shown in figure 2.

Over the next few days, we performed ventilator weaning, and the patient was successfully extubated after three days. On the 8<sup>th</sup> day, the polymerase chain reaction (PCR) swab result was negative, and the patient was moved to the regular ward after recuperating from COVID-19.

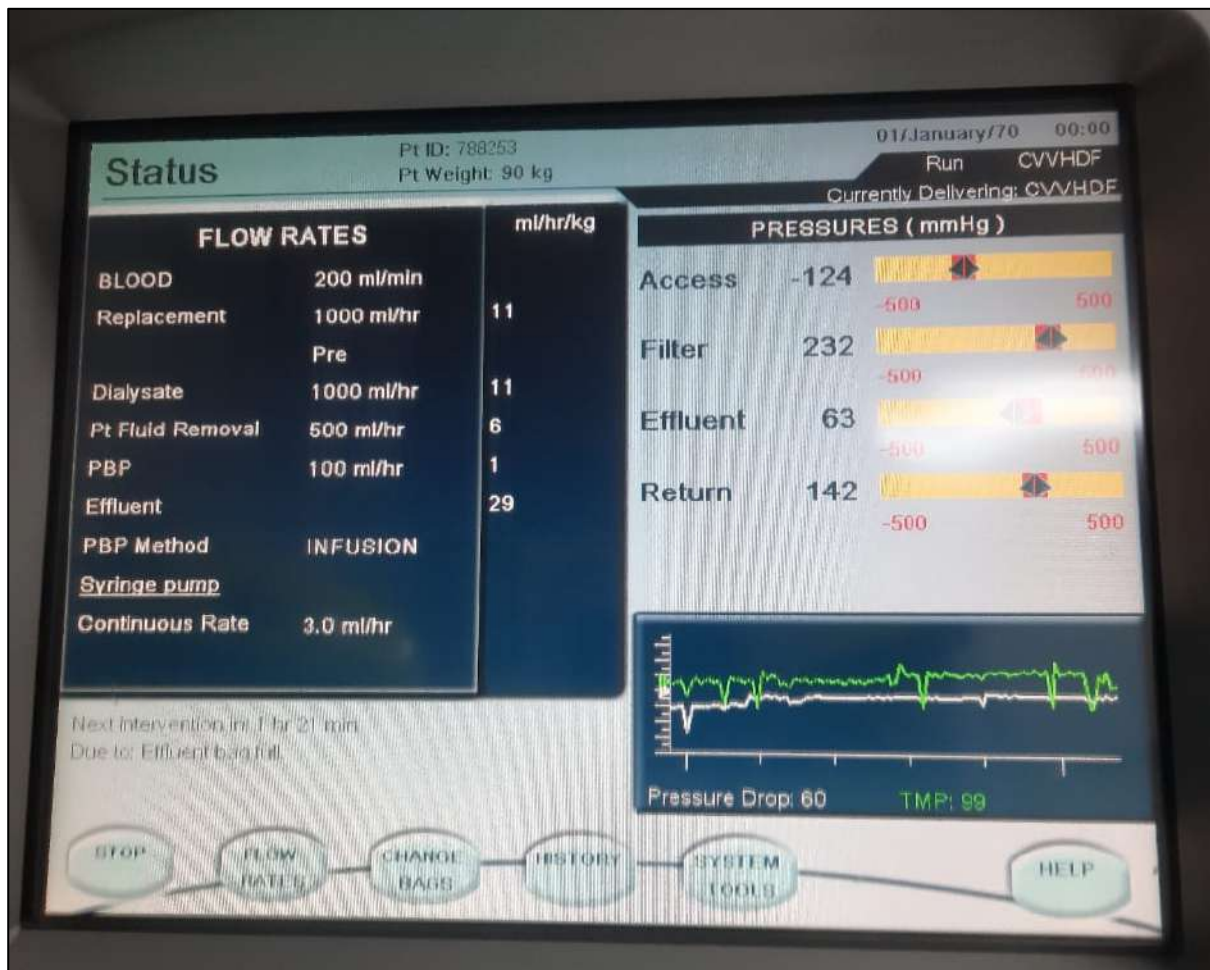


Figure 1. Dose settings of CVVHDF

## DISCUSSION

The COVID-19 pandemic has contributed to changes in medical procedures, including PCI in STEMI patients. This situation often causes delays in patients' assessment at the emergency department. Subsequently, strict infection control affects the working mechanism in our

catheterization laboratory. In this case, we decided to apply a central venous catheter and early intubation to minimize contamination.

RRT has been widely used in ICU settings, although the evidence to support the current practice is still limited. RRT plays a vital role in supporting renal dysfunction with multiple organ failure. (9) The major difference between CRRT and IRRT is the speed of removing water and waste. CRRT has become a preferable choice of RRT to treat AKI in ICU settings because of the advantage, such as the tolerance in unstable hemodynamic patients, as it removes water and waste at a slower rate. A systematic review by Rabindranath et al. reported no difference between the group treated with CRRT and IRRT in ICU mortality. Although many studies in this review showed that IRRT increases bleeding risk, it concluded no significant difference between these two groups. (10)

The mechanism of kidney injury associated with COVID-19 infection is unclear. Various hypotheses such as virus-induced cytopathy of renal tissue and sepsis due to cytokine storm might answer this. (11) In this case, we decided to treat the patient with CVVHDF due to COVID-19 infection. CVVHDF has been reported useful in eliminating inflammatory cytokines (TNF-alpha, IL-1 beta, IL-6, and IL-8) and endotoxin in patients with sepsis. (12)

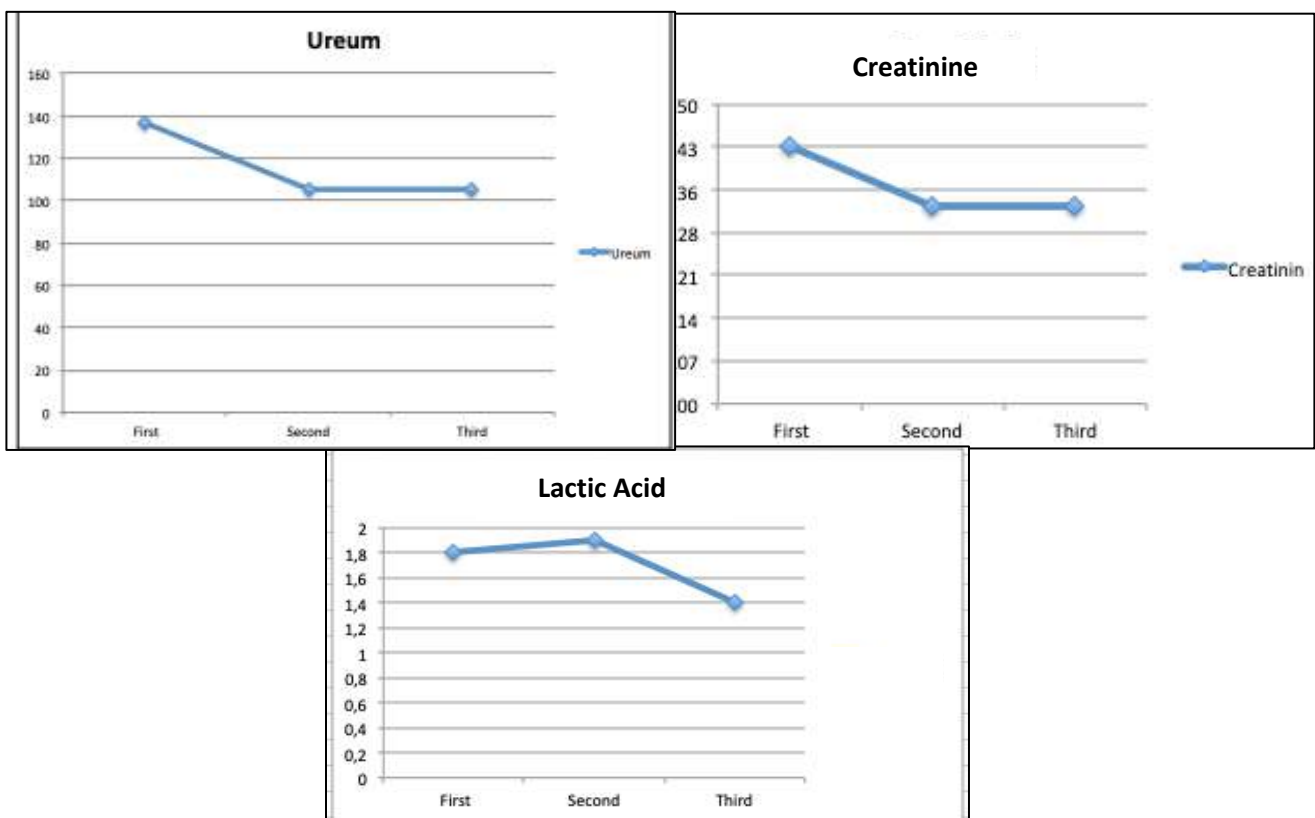


Figure 2. Improvement in the parameter of creatinine serum, ureum, and lactic acid after 24 hours of receiving CRRT.

The initiation time and period use of CRRT also play a vital role in the survival of AKI patients. Patients initiated on CRRT >6 days after the first diagnosis of AKI have higher mortality than patients who started earlier. The mortality rate also increases in patients exposed to CRRT treatment for >10 days (71.3% vs. 45.5%). (13) In this patient, we found that the treatment of CVVHDF for only 24 hours resulted in AKI resolution (decrease of serum creatinine and ureum level). We did not observe

any hemodynamic instability and elevated lactate levels during and after the treatment. Another reason for this successful treatment is probably because of the initiation time of CRRT treatment. We conducted this treatment for <6 days since the patient was first diagnosed with AKI.

The optimal dose of CRRT in treating AKI has not been established. The largest trial suggested no additional benefit when using the effluent flow rate of more than 20 mL/kg/hr. (14) To our knowledge, there is no published guideline about the dosing of CRRT in the treatment of AKI, whether it is caused by COVID-19 or other etiology. Therefore, the use of CRRT should be carefully assessed not only in terms of dosing but also in duration and initiation time.

## **CONCLUSION**

Early continuous renal replacement therapy might be beneficial in treating COVID-19 patients with AKI, who previously underwent percutaneous coronary intervention for ST-elevation myocardial infarction.

## **ABBREVIATIONS**

AKI, Acute Kidney Injury; PCI, percutaneous coronary intervention; GCS, Glasgow Coma Scale; CRRT, Continuous renal replacement therapy.

## **ETHICS APPROVAL AND INFORMED CONSENT**

The study protocol complies with the requirements of the institute's committee of Haji Adam Malik Hospital, Medan, Indonesia.

## **CONSENT FOR PUBLICATION**

The Authors agree to publication in Journal of Society Medicine.

## **DATA AVAILABILITY**

The datasets generated during and/or analyzed during the current study are available from the corresponding author upon reasonable request.

## **FUNDING**

None.

## **COMPETING INTERESTS**

None.

## **AUTHORS' CONTRIBUTIONS**

All authors significantly contribute to the work reported, whether in the conception, study design, execution, acquisition of data, analysis, and interpretation, or in all these areas. Contribute to drafting, revising, or critically reviewing the article. Approved the final version to be published, agreed on the journal to be submitted, and agreed to be accountable for all aspects of the work.

## **ACKNOWLEDGMENTS**

We would like to thank Universitas Sumatera Utara and Adam Malik Hospital Indonesia.

## REFERENCES

1. World Health Organization. Coronavirus Update (Live): 79,874,612 Cases and 1,751,965 Deaths from COVID-19 Virus Pandemic - Worldometer. Worldometers.info. World Health Organization. 2020. Available at: <https://www.worldometers.info/coronavirus/>
2. Liu Z., Bing X. and Zhi XZ. Epidemiology Working Group for NCIP Epidemic Response, Chinese Center for Disease Control and Prevention. The epidemiological characteristics of an outbreak of 2019 novel coronavirus diseases (COVID-19) in China. *Chin J Epidemiol.* 2020; 41: 145-51.
3. Richardson S., Hirsch J. S., Narasimhan M., Crawford J. M., McGinn T. and Davidson K. W., et al. Presenting Characteristics, Comorbidities, and Outcomes Among 5700 Patients Hospitalized With COVID-19 in the New York City Area. *JAMA.* 2020; 323: 2052-2059.
4. Chan L., Chaudhary K., Saha A., Chauhan K., Vaid A. and Zhao S., et al. AKI in Hospitalized Patients with COVID-19. *J Am Soc Nephrol.* 2020; 32: 151-160
5. Robbins-Juarez SY., Qian L., King KL., Stevens JS., Husain SA. and Radhakrishnan J., et al. Outcomes for patients with COVID-19 and acute kidney injury: a systematic review and meta-analysis. *Kidney International Reports.* 2020. 5: 1149-60.
6. Bruetto RG., Rodrigues FB., Torres US., Otaviano AP., Zanetta DM. and Burdmann EA. Renal function at hospital admission and mortality due to acute kidney injury after myocardial infarction. *PLoS One.* 2012. 7: e35496.
7. Cosentino N., Milazzo V., Campodonico J. and Marenzi G. 2017. Acute Kidney Injury in Patients with ST-Elevation Myocardial Infarction. *Journal of Heart and Stroke.* 2:1020.
8. Fox CS., Muntner P., Chen AY., Alexander KP., Roe MT. and Wiviott SD. Short-term outcomes of acute myocardial infarction in patients with acute kidney injury: a report from the National Cardiovascular Data Registry. *Circulation.* 2012. 125: 497-504.
9. Ahmed AR., Obilana A. and Lappin D. 2019. Renal Replacement Therapy in the Critical Care Setting. *Crit Care Res Pract.* 2019. 694810: 1-11.
10. Rabindranath K., Adams J., Macleod AM. and Muirhead N. Intermittent versus continuous renal replacement therapy for acute renal failure in adults. *Cochrane Database Syst Rev.* 2007; 3: CD003773.
11. Raina R., Chakraborty R., Sethi SK. and Bunchman T. Kidney replacement therapy in COVID-19 induced kidney failure and septic shock: a pediatric continuous renal replacement therapy [PCRRT] position on emergency preparedness with resource allocation. *Frontiers in pediatrics.* 2020;8: 413.
12. Peng Y., Yuan Z. and Li H. Removal of inflammatory cytokines and endotoxin by venovenous continuous renal replacement therapy for burned patients with sepsis. *Burns.* 2005; 3: 623-8.
13. Vats HS., Dart RA., Okon TR., Liang H. and Paganini EP. Does early initiation of continuous renal replacement therapy affect the outcome: experience in a tertiary care center. *Ren Fail.* 2011;33: 698-706.
14. Deepa C. and Muralidhar K. Renal replacement therapy in ICU. *J Anaesthesiol Clin Pharmacol.* 2012;28: 386-396.

How to cite

Lubis B, Amelia P, Akil M, Viandy V, Winata A, Yohanes WH George. Early Continuous Renal Replacement Therapy In Patients With St-Elevation Myocardial Infarction And Covid-19 After Percutaneous Coronary Intervention: A Case Report. Journal of Society Medicine. 2022;1(2): 66-72. DOI Link (<https://doi.org/10.25217/ji.vxix.xxxx>)